

## Assessment of the Efficacy of Cryolipolysis on Saddlebags: A Prospective Study of 53 Patients

Lucille Adjadj, M.D.  
Mounia SidAhmed-Mezi,  
Ph.D.  
Marine Mondoloni, M.D.  
Jean Paul Meningaud, M.D.,  
Ph.D.  
Barbara Hersant, M.D.  
*Créteil, France*



**Background:** Cryolipolysis is a noninvasive subcutaneous fat removal technique. Its efficacy has been demonstrated on various fatty areas but not yet on saddlebags. The main objective of this study was to demonstrate the efficacy, patient tolerance, and safety of cryolipolysis on the saddlebags.

**Methods:** This prospective study enrolled 53 patients with saddlebags. Patients with a history of liposuction or other surgical procedure on the saddlebag area and those on diet pills were excluded. The primary endpoint was a decrease in fat thickness at 3 and 6 months, as assessed by thigh circumference measurement and by ultrasound evaluation of subcutaneous fat. Pain associated with cryolipolysis was assessed using a visual analogue scale. Body mass index at the different time points and adverse events were recorded. All patients completed a satisfaction questionnaire at the end of the study.

**Results:** At 6 months, there was a mean decrease of 5.63 cm in thigh circumference; the mean decrease in fat layer thickness measured by ultrasound was 1.31 cm. The satisfaction questionnaire showed that 93.75 percent of patients were satisfied with the results. The mean visual analogue scale score was 1.66 of 10 after the session. Reversible skin changes such as postprocedure postinflammatory hyperpigmentation were observed in 8.33 percent of patients.

**Conclusions:** Cryolipolysis is an effective technique for reducing saddlebag fat and is well tolerated by patients. A substantial risk of skin lesions, including postinflammatory hyperpigmentation that resolved after a few months, was observed. Cryolipolysis is a good alternative to liposuction in women with moderate, well-localized saddlebags. (*Plast. Reconstr. Surg.* 140: 50, 2017.)

**CLINICAL QUESTION/LEVEL OF EVIDENCE:** Therapeutic, IV.

In women, the fat mass represents 20 to 25 percent of the total body weight. There are two types of fat: subcutaneous fat, also known as “genetic” fat; and deeper “metabolic” fat. The fascia superficialis separates the two. The presence of excessive fat deposits has consequences, both physical (e.g., increased risk for cardiovascular disease, type 2 diabetes mellitus, some cancers, joint disorders) and psychological (e.g., negative body image, social rejection).<sup>1</sup> Measures to reduce body fat deposits need to be implemented; however, genetic fat is not much affected by the usual measures of diet and exercise, as it is resistant to the effects of catecholamines and is sometimes also insulin-resistant. This is true of fat in the saddlebag area. The saddlebags are constitutional excess

fat in the trochanteric region in young women. Body aging may also be accompanied by excessive fat deposits in this area. The saddlebag area is different from other areas with excessive fat deposits in that it is also a fibrous area.<sup>1,2</sup>

Surgical treatment is one option for fat removal. There is rising demand worldwide for procedures for fat mass removal for cosmetic reasons.<sup>3</sup> Liposuction is a commonly used procedure; however, it requires local or general anesthesia and is associated with acute complications such as hematoma, hemorrhage, and edema, in addition to long-term sequelae such as permanent skin surface irregularities, skin sagging, and cellulite worsening. Several noninvasive techniques such as low-level laser therapy, high-intensity focused ultrasound, radiofrequency, and cryolipolysis have also been used to reduce subcutaneous fat through adipocyte apoptosis or necrosis. Cryolipolysis is

*From the Department of Plastic and Cosmetic Reconstructive Surgery and Maxillofacial Surgery, Henri Mondor Hospital.*

*Received for publication May 26, 2016; accepted November 22, 2016.*

*Copyright © 2017 by the American Society of Plastic Surgeons*

DOI: 10.1097/PRS.0000000000003433

**Disclosure:** *The authors have no financial interest to declare in relation to the content of this article.*

presently accepted as the gold-standard noninvasive technique for subcutaneous fat reduction in areas such as the abdomen, flanks, inner knees, inner thighs, back, and arms.<sup>3-5</sup> Its efficacy in these areas has been demonstrated,<sup>6</sup> but there has been only one study to date on cryolipolysis in the saddlebag area.<sup>7</sup> The main objective of the present study was to demonstrate the efficacy of cryolipolysis on saddlebag excess fat and to examine patient tolerance and the safety of the procedure.

## PATIENTS AND METHODS

The study was conducted in accordance with globally accepted standards of Good Clinical Practice (ICH-E6), European Directive 2001/20/EC, and the revised version of the Declaration of Helsinki set out in the European Directive. All patients provided written informed consent to participate. This prospective study enrolled 53 volunteer women with localized excessive fat deposits at the saddlebags. Patients were excluded if they had (1) a history of liposuction or other surgical procedure on the saddlebag area, (2) been taking diet pills 1 year preceding the session, (3) a history of an eating disorder, or (4) any contraindication to the procedure.

### Methods

Cryolipolysis was performed using CryoSlim (BFP Electronique, Montrodât, France) (Fig. 1). The same operator (A) performed the procedure in all patients. Each patient underwent one cryolipolysis session of 55 minutes at a temperature of  $-2^{\circ}\text{C}$  and a depression of  $-300$  mbar centered on the saddlebags, followed by 5 minutes of energetic manual massage with kneading motions (this is the approach used in most aesthetic centers in France).

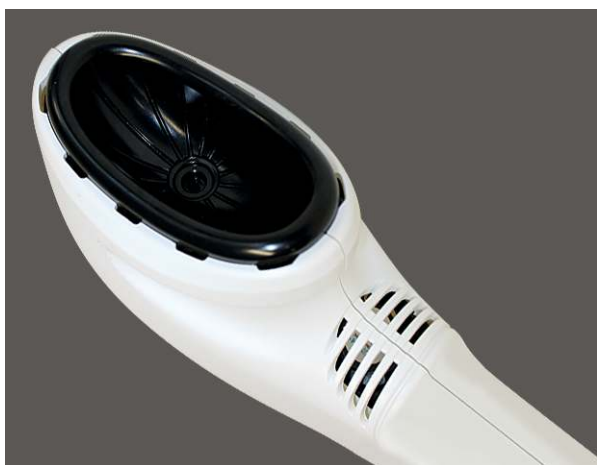

Fig. 1. Handpiece

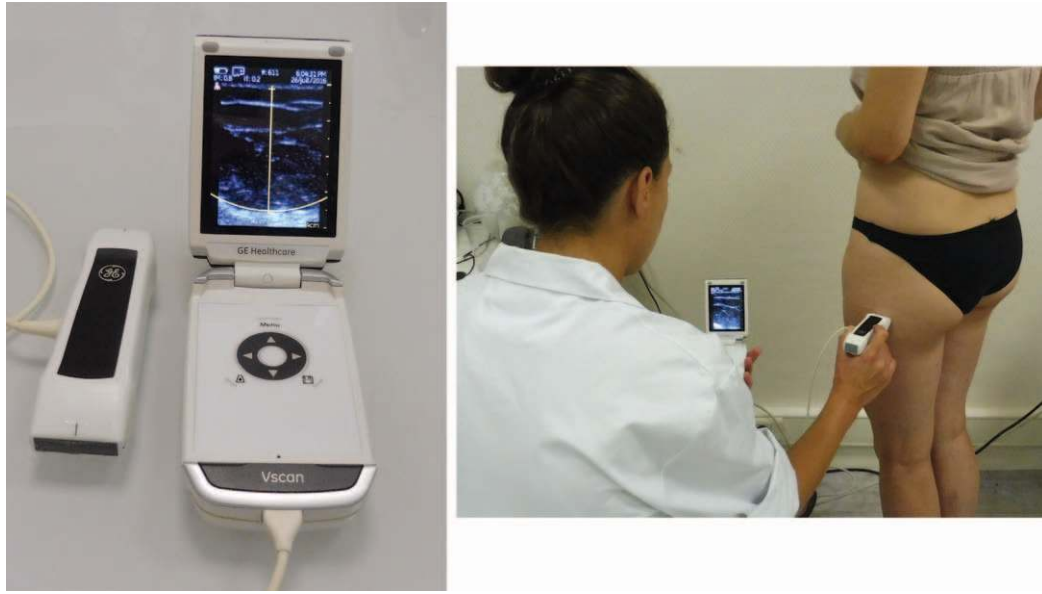The procedure was performed with the patient in the prone position. No analgesics or sedatives were administered before the procedure. The cryode was placed directly on the skin; no strap was used because the cryode aspiration of  $-300$  mbar enabled its fixation on the skin in less than 2 minutes. However, pillows were placed under the cryodes to ensure patient comfort and prevent the tissues being pulled down by the cryode fixed on the skin. The handpiece was  $25 \times 15$  cm, with an oval form that was adapted to the saddlebags and covered them entirely. Both thighs received the same treatment. The cryolipolysis cryodes were disinfected between each use. No pain medication was administered after the session. Patients were allowed to resume their daily activities immediately after the session. They were asked not to change their lifestyle (particularly with regard to diet and daily exercise) during the study period.

The primary endpoint was the decrease in saddlebag pannus thickness as assessed by change in thigh circumference and ultrasound measurement of subcutaneous fat layer thickness at 3 and 6 months. Thigh circumference (in centimeters) was measured by the same operator (B) in all patients; measurement was made in both thighs at the level of the greater trochanter, with the patient standing and with their feet together. The Vscan ultrasound system (GE Healthcare, Vingmed Ultrasound AS, Horten, Norway) was used for measuring subcutaneous fat layer thickness (on the same side for each patient in alignment with the most projected area of the excess fat) before the session and at 3 and 6 months after treatment (Fig. 2).

A visual analogue scale, ranging from 0 (no pain) to 10 (severe pain), was used to assess patient tolerance of the procedure. All adverse events were recorded (operator A). Frontal, back, and right and left profile photographs were taken before the session and at 3 and 6 months after the procedure for each patient. At the final follow-up at 6 months, all patients completed a 10-item satisfaction questionnaire.

### Statistical Analysis

Graphical representations and statistical analysis were performed using JMP 12 software (SAS Institute, Inc., Cary, N.C.). A linear model with leverage test was used to compare the results of different parameters over time. Means were compared using one-way analysis of variance followed by a post hoc Dunnett test. Statistical significance was set at  $p \leq 0.05$ .



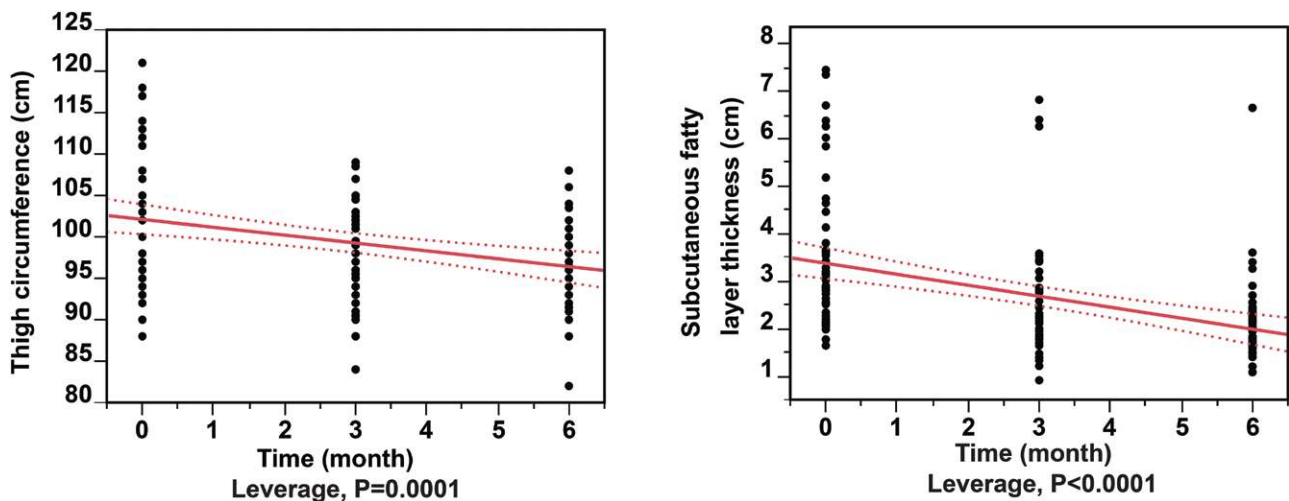
**Fig. 2.** Measurement of subcutaneous fat thickness with ultrasound. The measurement was performed with the ultrasound probe held perpendicular to the skin surface; the measurement was obtained at the point where the subcutaneous fat layer was thickest.

### RESULTS

Of the 53 patients enrolled in the study, five were lost to follow-up (two at the 3-month visit and three at the 6-month visit). The results for the remaining 48 patients were included in the final analysis. The mean age of the patients was  $38 \pm 11$  years. The mean body mass index was  $23.61 \pm 3.91$  kg/m<sup>2</sup> at baseline,  $23.54 \pm 3.71$  kg/m<sup>2</sup> at 3 months, and  $23.25 \pm 3.79$  kg/m<sup>2</sup> at 6 months ( $p = 0.559$ ). Analysis of the linear model (Fig. 3) showed a significant decrease in thigh circumference ( $p = 0.0001$ ) and in subcutaneous fat layer thickness ( $p < 0.0001$ ). The mean thigh circumference was  $102.56 \pm 8.3$  cm at

day 0,  $99.75 \pm 5.75$  cm at 3 months ( $p = 0.006$ ), and  $96.93 \pm 5.57$  cm at 6 months ( $p = 0.0003$ ) (Table 1). The mean decrease in thigh circumference was 2.81 cm (2.7 percent) at 3 months and 5.63 cm (5.5 percent) at 6 months (Fig. 4). The mean subcutaneous fat layer thickness was  $3.4 \pm 1.51$  cm at day 0,  $2.45 \pm 1.25$  cm at 3 months ( $p = 0.0002$ ), and  $2.09 \pm 0.87$  cm at 6 months ( $p < 0.001$ ) (Table 1). The mean decrease in fat layer thickness was 0.95 cm (27.95 percent) at 3 months and 1.31 cm (38.53 percent) at 6 months.

With regard to adverse events, 30 patients (62.5 percent) experienced erythema after the



**Fig. 3.** Multiple linear analysis of the thigh circumference (left) and the saddlebag fat layer thickness (right).

**Table 1. Results of Thigh Circumference and Subcutaneous Fat Thickness Measured at Day 0, 3 Months, and 6 Months**

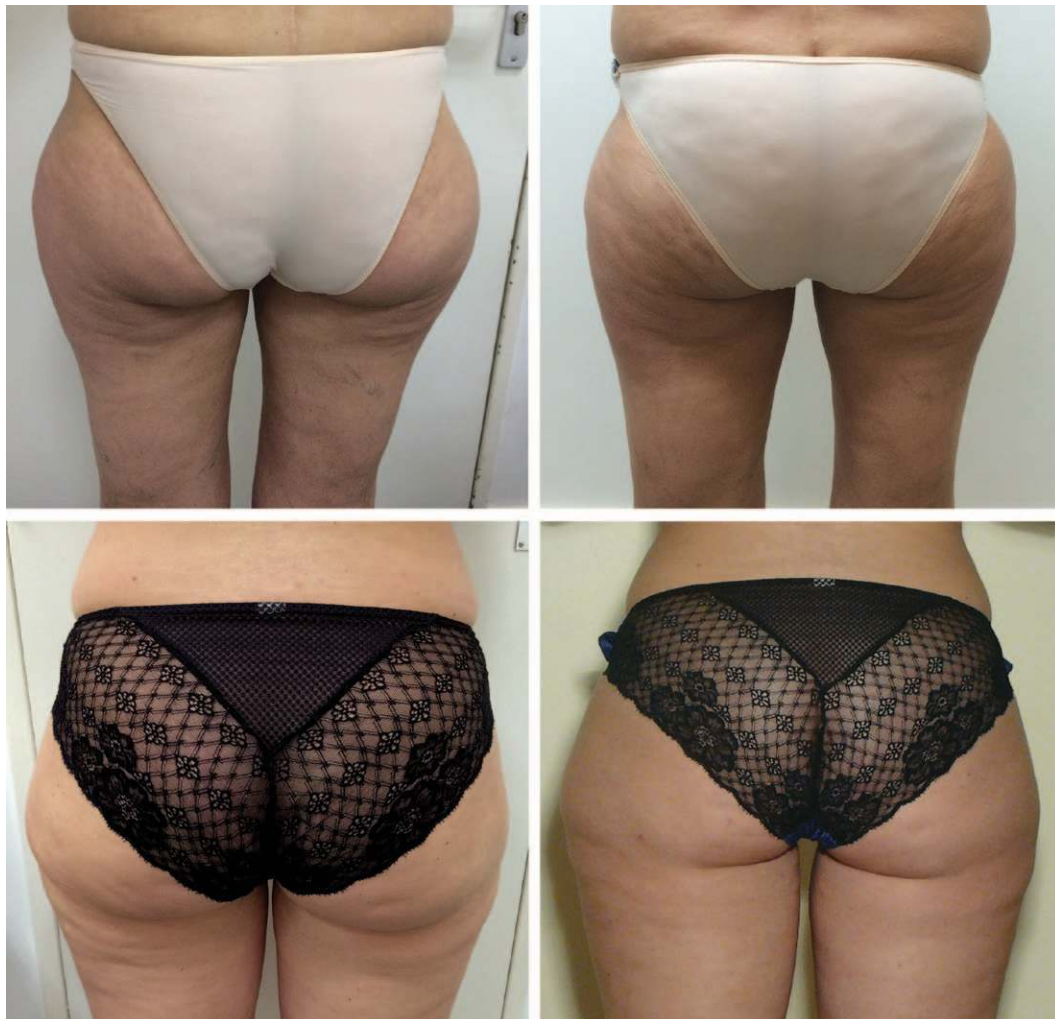	Day 0	3 Mo	6 Mo	<i>p</i> *	
				Day 0 vs. 3 Mo	Day 0 vs. 6 Mo
Mean thigh circumference ± SD, cm	102.56 ± 8.31	99.75 ± 5.75	96.93 ± 5.57	0.006	0.0003
Mean subcutaneous fat thickness ± SD, cm	3.4 ± 1.51	2.45 ± 1.25	2.09 ± 0.87	0.0002	0.001

\*One-way analysis of variance followed by a post hoc Dunnett test.

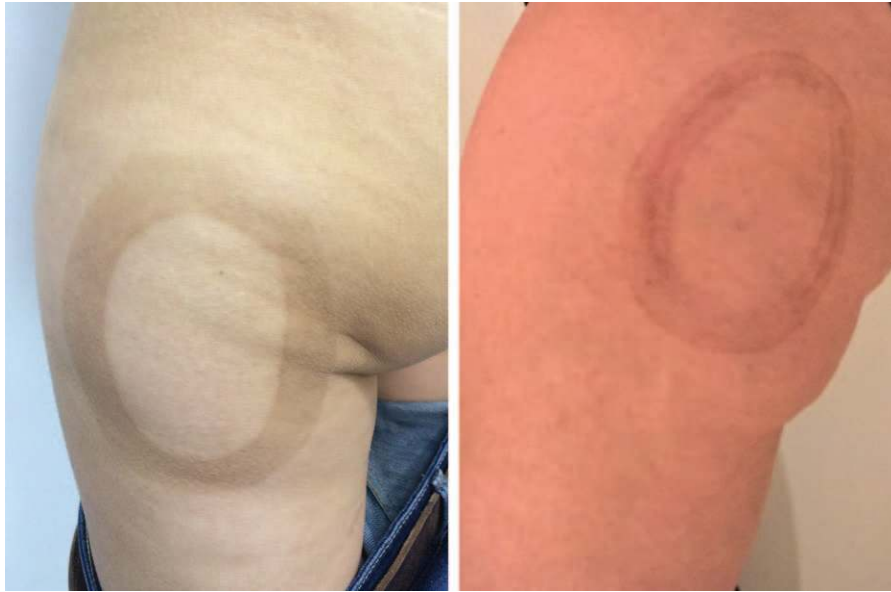session; the erythema subsided after a mean duration of 15 hours. Skin hyperpigmentation corresponding to the shape of the handpiece was seen on day 2 in four patients (8.33 percent) (Fig. 5). This was diagnosed as postinflammatory hyperpigmentation at the Department of Dermatology and treated with a dermocorticoid cream and a skin emollient. At 6-month follow-up the pigmentation was still present for one patient but was considerably reduced (Fig. 6). We contacted this patient at 1 year after treatment and this hyperpigmentation

was gone. There were no delayed adverse events in any patient.

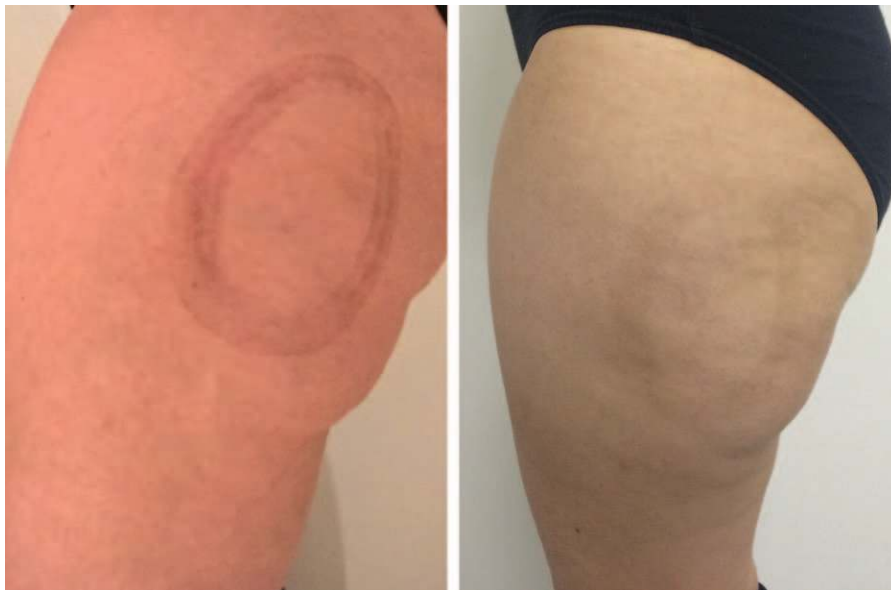The patient satisfaction questionnaire completed at the end of the study showed that the majority of patients were satisfied with the results of the procedure, with 47 patients (89.58 percent) stating that they would recommend cryolipolysis for treatment of saddlebags to their friends (Table 2). Of the 48 patients, 44 (83.33 percent) underwent a further cryolipolysis session on another body area.



**Fig. 4.** Photographs of patients with saddlebags at day 0 (left) and at 6 months (right).



**Fig. 5.** Two examples of cryolipolysis-induced hyperpigmentation. The photographs were taken 15 days after treatment.



**Fig. 6.** Progressive decrease in hyperpigmentation after cryolipolysis: 2 weeks after treatment (*left*) and 6 months after treatment (*right*).

## DISCUSSION

In this study, we examined the efficacy of cryolipolysis in the treatment of the saddlebag area in women and found that the method could produce significant reduction in subcutaneous fat layer thickness and thigh circumference. There were only a few minor adverse events, and patient satisfaction was high.

Adipocytes are the most cold-sensitive cells. Cryolipolysis induces permanent, selective,

subcutaneous adipocyte damage. It reproduces cold panniculitis, leading to lipoatrophy followed by progressive removal of apoptotic fat cells.<sup>8</sup> The lower the temperature and the longer the exposure, the faster the progression of adipocytes toward apoptosis.<sup>9</sup> The pathophysiology of fat removal is explained by a periadipocyte lymphocytic inflammatory infiltration, which is related to the crystallization of triglycerides. The intensity of the lymphocyte infiltration correlates well with the

**Table 2. Results of the Patient Satisfaction Questionnaire Completed 6 Months after Cryolipolysis\***

Question	%
1. Are you overall satisfied to have undergone a saddlebag cryolipolysis session?	93.75
2. Would you recommend this session to your friends?	89.58
3. Did you experience pain after the session? If yes, for how long?	8.33†
4. Did you experience a postsession erythema? If yes, for how long?	62.5‡
5. Did your skin aspect improve after the session (cutaneous trophicity, cellulite)? If yes, which one?	56.25
Trophicity	45.83
Cellulite	35.42
6. If your skin aspect improved, did it last until now?	50
7. Do you have cryolipolysis sequelae (pain, sensitivity disorder, hypopigmentation/hyperpigmentation) today?	
Pain	0
Sensitivity disorder	0
Hyperpigmentation	2.08
8. After this first experience of cryolipolysis centered on the saddlebags, would you be interested in undergoing a session on other areas of your body?	83.33

\*Results are expressed as a percentage of positive responses.

†2 hr 30 min per patient.

‡15 hr per patient.

rate of fat removal. The lymphocyte infiltration is followed by macrophage phagocytosis and interlobular septal breaks.<sup>9</sup> The inflammatory process starts 2 to 14 days after treatment and continues for up to at least 4 months.<sup>10</sup>

Cryolipolysis is considered a safe procedure. The few contraindications include cryoglobulinemia, paroxysmal hemoglobinuria, cold urticaria, and local skin lesions.

The sequence of events following cryolipolysis has been previously studied. In a prospective study conducted on pigs, the researchers used histologic analysis to examine the effect of cryolipolysis on subcutaneous fat. They found that between day 0 and day 30, the adipocyte lipid fraction decreased from 97 percent to 52 percent because of a periadipocyte inflammation followed by irreversible apoptosis and macrophage phagocytosis.<sup>9</sup> Excellent hematologic and neurologic tolerance has been demonstrated, with the lipid profile and liver function being unaffected by cryolipolysis.<sup>11,12</sup> Furthermore, neurologic assessment and biopsy have shown no evidence of peripheral nerve injury.<sup>13</sup>

An earlier clinical study by Dierickx et al., which included 518 patients, showed a mean decrease in subcutaneous fat layer thickness by 22.4 percent at 4 months and 22.5 percent at 6 months.<sup>14</sup> In our study, we observed significant decrease in thigh circumference (by 5.5 percent, or 5.63 cm) and in subcutaneous fat thickness (by 38.53 percent, or 1.31 cm) at 6 months. All of our patients experienced a decrease in subcutaneous fat thickness at 3 and 6 months, regardless of whether or not they had any change in weight.

There has been only one earlier study that has focused on the cryolipolysis in the saddlebag area.<sup>14</sup> The study included 40 patients who underwent a 2-hour session. The authors reported a 2.6-cm

decrease in subcutaneous fat thickness as measured by ultrasound at 4 months. Unfortunately, the authors do not specify the temperature used and the presence or absence of depression of the cryodes. Moreover, no manual massage was performed, and the follow-up period was only 4 months.

The effect of postsession energetic manual massage has been studied earlier in a series of 17 patients who underwent massage of only 2 minutes after a 1-hour cryolipolysis session. The study showed highly satisfactory results in terms of increased efficacy and no increased risk of adverse effects.<sup>15</sup>

A limited number of studies have assessed the long-term efficacy of cryolipolysis. Bernstein showed that the effect of subfascial fat removal persisted even 5 years after cryolipolysis, regardless of patient weight change, indicating that there was no adipocyte regeneration in the treated area.<sup>5,16</sup> Our study showed that the beneficial effect of cryolipolysis on the reduction in subcutaneous fat layer thickness lasts at least up to 6 months.

In our series, we observed seven patients (14.58 percent) who had thigh circumference stabilization or increase despite having an ultrasound-demonstrated decrease in subcutaneous fat thickness. All patients whose thigh circumference increased had gained at least 1 body mass index point over the baseline body mass index. We considered the possibility that stabilization or increase in thigh circumference at the follow-up visit was related to the menstrual cycle. On questioning the patients, we found that 86 percent (six of seven) were in the premenstrual or perimenstrual phase, which suggests that hormone-induced tissue edema may have been responsible for the increase in thigh circumference in these patients.<sup>17</sup>

Cryolipolysis has been used in combination with external ultrasound. The combination appears to alter the structure of collagen fibers and is associated with improved microcirculation because of neoangiogenesis. Excellent results in terms of skin trophicity and reduction in subcutaneous fat thickness have been demonstrated with combined therapy. In 50 patients with saddlebags, mean reductions of 3.02 cm in subcutaneous fat thickness and 4.45 cm in thigh circumference were observed.<sup>18</sup>

In our study, before the procedure, patients were informed that they could experience post-cryolipolysis numbness. This did occur in all patients, but it resolved completely in less than 4 hours. One study that included 438 patients assessed the safety of cryolipolysis.<sup>8</sup> No moderate/severe or prolonged adverse event was encountered over 4 weeks of follow-up. The adverse effects seen included erythema lasting 10 minutes (100 percent); discomfort during the first 8 minutes of treatment (100 percent); bruising (8.4 percent); hypoesthesia/dysesthesia/pruritus at the treated area, which resolved in less than 1 month (0.4 percent); and clinically significant panniculitis, which resolved in less than 1 month (2.5 percent). There were no cases of hematoma or skin necrosis. The authors concluded that cryolipolysis had excellent safety. In our study, we observed four cases (8.33 percent) of postcryolipolysis hyperpigmentation. This was probably because we used a temperature of  $-2^{\circ}\text{C}$ , whereas a temperature of  $0^{\circ}\text{C}$  or  $-0.5^{\circ}\text{C}$  is generally used.<sup>15,18</sup> All cases of hyperpigmentation occurred in patients with a dark skin phototype (Fitzpatrick type III/IV). In three patients, the hyperpigmentation had completely resolved at the 6-month visit; in one patient (2.08 percent), although the hyperpigmentation persisted, it was considerably reduced, suggesting that it would likely disappear over the coming months (Figs. 4 through 6). Two mechanisms could be responsible for the postcryolipolysis hyperpigmentation: burns and hemosiderin deposition in the dermis.<sup>19</sup> The use of an interface may decrease the likelihood of this complication.

Before undergoing cryolipolysis, patients should be informed of the potential risk of skin lesions such as hyperpigmentation or erythema (appearing, on average, 15 hours after cryolipolysis). The risk of skin lesions is minimal compared with liposuction, which systematically causes considerable and often painful postoperative bruising, associated with thin subcutaneous hematomas. Patients should also be warned of the small risk of paradoxical adipose hyperplasia, which is seen in one in 20,000 treated patients (an incidence rate

of 0.0051 percent). However, the risk of long-term skin lesions is still unknown.<sup>20,21</sup>

## CONCLUSIONS

Cryolipolysis is a noninvasive technique that could be a good alternative to liposuction in patients with moderate excess fat. This prospective study showed that cryolipolysis is well tolerated and effective for reduction of saddlebags; it produced significant decreases in thigh circumference by 5.63 cm and subcutaneous fat thickness measured by ultrasound by 1.31 cm at 6 months. Only minor self-limited skin lesions such as hyperpigmentation and erythema were encountered. Studies are needed to determine whether the use of an interface between the applicator and the patient will help lessen or eliminate skin sequelae. It would also be interesting to determine the duration of the efficacy of cryolipolysis after a single session and the ideal temperatures to be used on different body areas to optimize the efficacy of the procedure without increasing the risks. The use of a three-dimensional camera for accurate quantification of the amount of fat that is phagocytized should also be considered.

*Barbara Hersant, M.D.*

Department of Plastic and Cosmetic Reconstructive  
Surgery and Maxillofacial Surgery  
Henri Mondor Hospital  
51 avenue du Maréchal de Lattre de Tassigny  
Créteil 94010, France  
barbara.hersant@gmail.com

## REFERENCES

1. Dardour JC. New anatomo clinic approach of adipose tissue (in French). *Ann Chir Plast Esthet.* 2012;57:454-464.
2. Bousquet-Rouaud R, Mazer JM. La silhouette: Ultrasons focalisés, cryolipolyse, lumières basse énergie, radiofréquence. Ultrasons focalisés, cellulite, surcharge graisseuse. *Ann Dermatol Venerol.* 2014;141:28.
3. Kennedy J, Verne S, Griffith R, Falto-Aizpurua L, Nouri K. Non-invasive subcutaneous fat reduction: A review. *J Eur Acad Dermatol Venerol.* 2015;29:1679-1688.
4. Krueger N, Mai SV, Luebberding S, Sadick NS. Cryolipolysis for noninvasive body contouring: Clinical efficacy and patient satisfaction. *Clin Cosmet Investig Dermatol.* 2014;7:201-205.
5. Bernstein EF. Longitudinal evaluation of cryolipolysis efficacy: Two case studies. *J Cosmet Dermatol.* 2013;12:149-152.
6. Bernstein EF, Bloom JD, Basilavecchio LD, Plugis JM. Non-invasive fat reduction of the flanks using a new cryolipolysis applicator and overlapping, two-cycle treatments. *Lasers Surg Med.* 2014;46:731-735.
7. Stevens WG, Bachelor EP. Cryolipolysis conformable-surface applicator for nonsurgical fat reduction in lateral thighs. *Aesthet Surg J.* 2015;35:66-71.
8. Mazer JM, Naouri M, Arigon V, Koenig-Bancel S, Sand M. Tolérance clinique de la cryolipolyse CoolSculpting Zeltiq. *Ann Dermatol Venerol.* 2013;140:200.

9. Manstein D, Laubach H, Watanabe K, Farinelli W, Zurakowski D, Anderson RR. Selective cryolysis: A novel method of non-invasive fat removal. *Lasers Surg Med.* 2008;40:595–604.
10. Nelson AA, Wasserman D, Avram MM. Cryolipolysis for reduction of excess adipose tissue. *Semin Cutan Med Surg.* 2009;28:244–249.
11. Zelickson B, Hegbert B, Preciado J, et al. Cryolipolysis for noninvasive fat cell destruction: Initial results from a pig model. *Dermatol Surg.* 2009;35:1462–1470.
12. Klein KB, Zelickson B, Riopelle JG, et al. Non-invasive cryolipolysis for subcutaneous fat reduction does not affect serum lipid levels or liver function tests. *Lasers Surg Med.* 2009;41:785–790.
13. Coleman SR, Sachdeva K, Egbert BM, Preciado J, Allison J. Clinical efficacy of noninvasive cryolipolysis and its effects on peripheral nerves. *Aesthetic Plast Surg.* 2009;33:482–488.
14. Dierickx CC, Mazer JM, Sand M, Koenig S, Arigon V. Safety, tolerance, and patient satisfaction with noninvasive cryolipolysis. *Dermatol Surg.* 2013;39:1209–1216.
15. Boey GE, Wasilenchuk JL. Enhanced clinical outcome with manual massage following cryolipolysis treatment: A 4-month study of safety and efficacy. *Lasers Surg Med.* 2014;46:20–26.
16. Zelickson BD, Burns AJ, Kilmer SL. Cryolipolysis for safe and effective inner thigh fat reduction. *Lasers Surg Med.* 2015;47:120–127.
17. Tacani PM, Ribeiro Dde O, Barros Guimarães BE, Machado AF, Tacani RE. Characterization of symptoms and edema distribution in premenstrual syndrome. *Int J Womens Health.* 2015;7:297–303.
18. Ferraro GA, De Francesco F, Cataldo C, Rossano F, Nicoletti G, D’Andrea F. Synergistic effects of cryolipolysis and shock waves for noninvasive body contouring. *Aesthetic Plast Surg.* 2012;36:666–679.
19. Hamilton HK, Dover JS, Arndt KA. Successful treatment of disfiguring hemosiderin-containing hyperpigmentation with the Q-switched 650-nm wavelength laser. *JAMA Dermatol.* 2014;150:1221–1222.
20. Selina M, Singh MD, Elizabet RC, Geddes MD, Sean G. Paradoxical adipose hyperplasia secondary to cryolipolysis: An underreported entity? *Lasers Surg Med.* 2015;47:476–478.
21. Ingargiola MJ, Motakef S, Chung MT, Vasconez HC, Sasaki GH. Cryolipolysis for fat reduction and body contouring: Safety and efficacy of current treatment paradigms. *Plast Reconstr Surg.* 2015;135:1581–1590.